

Research Paper

Does liquid nitrogen recycled autograft for treatment of bone sarcoma impact local recurrence rate? A systematic review

Ana Cecilia Belzarena^{*}, James L. Cook

Department of Orthopaedic Surgery, University of Missouri Hospital, Columbia, MO, United States

HIGHLIGHTS

- Surgical resection with wide margins has been gold standard treatment for bone sarcomas.
- Recycling resected bone with liquid nitrogen offers various advantages but has limited acceptance due to concerns about local recurrence.
- A systematic review of literature from 2008 to 2023 identified 16 studies involving 286 patients with primary bone sarcoma treated with liquid nitrogen recycled autografts.
- Local recurrence occurred in 8.7% of these patients within the first four years.
- Liquid nitrogen recycled autograft technique compares favorably to other limb salvage options.

ARTICLE INFO

Keywords:

Bone sarcoma
Recycled autograft
Liquid nitrogen

ABSTRACT

The gold standard treatment for primary bone sarcomas has been surgical resection with wide margins. However, there is no consensus regarding an optimal method for limb salvage reconstruction. In 2005, a technique for recycling resected bone after intraoperative treatment with liquid nitrogen was described. This technique has been reported to have a spectrum of advantages; nonetheless, acceptance for routine use has been limited, primarily for fear of local recurrence. A systematic search of the literature using PubMed and Google Scholar was performed. Full-text articles published between 2008 and 2023 were included if the study presented sufficient information regarding patients with a diagnosis of a primary bone sarcoma of the limbs or pelvis who had undergone reconstruction with liquid nitrogen recycled autografts. Sixteen studies that included 286 patients met criteria for analyses. Local recurrence occurred in 25 patients (8.7 %) during the first 4 years following limb salvage reconstruction using recycled autografts for treatment of primary bone sarcomas, which compares favorably to the 15–30 % local recurrence rates reported for patients undergoing limb salvage reconstruction using artificial implants. Systematic synthesis of the current evidence regarding local recurrence rates following use of the liquid nitrogen recycled autograft technique for limb salvage reconstruction after bone sarcoma resection suggests a favorable comparison to other limb salvage reconstruction options. As such, this technique warrants further consideration as a viable option for indicated patients based on relative advantages regarding costs, availability, and biologic and surgical reconstruction benefits.

1. Introduction

Primary bone sarcomas are rare tumors that originate from mesenchymal cells [1]. These tumors, most commonly found along the metaphysis of long bones, constitute 0.2 % of annual cancer diagnoses in the United States (US) [2,3]. Ewing sarcoma and osteosarcoma are more frequent in children and adolescents, whereas chondrosarcoma and chordomas are more prevalent in older patients [4,5]. The gold standard

treatment for primary bone sarcomas has been surgical resection of the tumor with wide margins [6]. Depending on subtype, neoadjuvant chemotherapy may be indicated, which may be followed by a second round of systemic treatment as well as radiotherapy [7,8].

Since the emergence of effective adjuvant treatment options, most patients are offered a limb salvage option for surgical treatment of primary bone sarcomas [6,9]. For these options, there is no dispute regarding the importance of resecting the tumor with negative margins

^{*} Corresponding author.

E-mail addresses: acb4cq@health.missouri.edu, acbelzarenagenovese@health.missouri.edu (A. Cecilia Belzarena).

<https://doi.org/10.1016/j.jbo.2024.100628>

Received 2 June 2024; Received in revised form 4 August 2024; Accepted 5 August 2024

Available online 8 August 2024

2212-1374/© 2024 The Author(s). Published by Elsevier GmbH. This is an open access article under the CC BY-NC-ND license (<http://creativecommons.org/licenses/by-nc-nd/4.0/>).

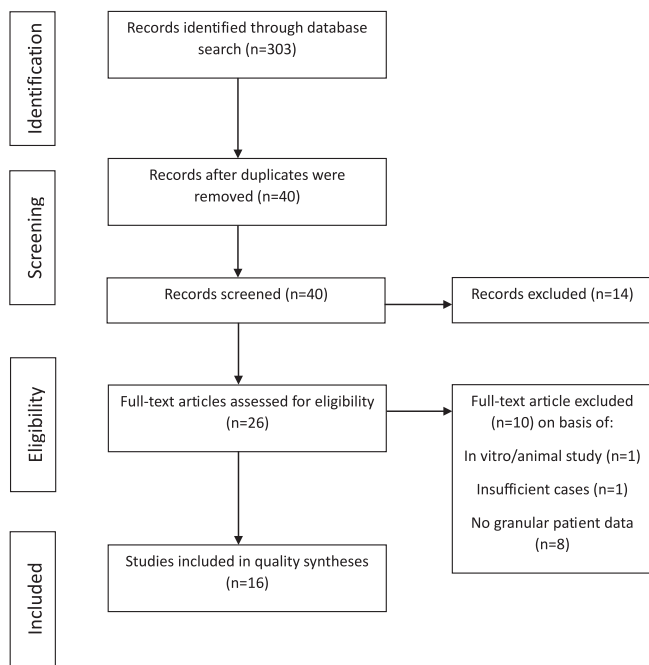


Fig. 1. Prisma Flow chart.

as a key prognostic factor for these patients. However, there is no evidence-based consensus regarding an optimal method for limb salvage reconstruction after tumor resection. In the US and some parts of Europe, limb salvage reconstructions of the resected bone are most often performed using megaprotheses or a combination of implants and allografts [9,10]. Reconstruction using allograft only or a combination of allograft and vascularized fibula autograft has also been reported [11]. However, based on cultural preferences, costs, and availability, in many parts of the world there is widespread use of the “recycled autograft” technique first described by Prof. Tsuchiya in 2005 in which the patient’s resected bone is intraoperatively treated with liquid nitrogen at -196°C for 20 min to destroy neoplastic cells followed by immediate reimplantation for limb salvage reconstruction [12,13,14]. The bone to be treated can be fully separated from unaffected bone (free technique) or left attached at one end (pedicle technique) [15]. After treatment, the segment is anatomically reattached to host using internal fixation, alone or in combination with a vascularized fibula autograft [16] or artificial joint replacement [17].

Table 1
Included studies list.

STUDIES Study	Year	Patients (n = 286)	Diagnosis (n)	Follow-up (mean, median)	Local Recurrence (n, %)	Level of Evidence
1. Abdel et al.[19]	2009	10	OS (10)	54, 54	0	IV
2. Dai et al.[41]	2023	5	OS (10)	24–36*	0	IV
3. Emet et al.[42]	2023	7	ES (6), OS (1)	33, 25	1 (14.3 %)	IV
4. Garg et al.[43]	2020	10	ES (7), OS (2), Other (1)	40, 42	0	IV
5. Hayashi et al.[20]	2020	22	OS (17), CH (3), ES (2)	19, 15	0	IV
6. Higuchi et al.[44]	2017	18	OS (18)	48, 45	0	IV
7. Hindiskere et al.[45]	2020	41	OS (30), ES (8), Other (3)	20, 21	1 (2.4 %)	IV
8. Igarashi et al.[18]	2014	28	OS (19), CH (5), Other (4)	103, 99	4 (14.3 %)	IV
9. Li et al.[46]	2016	8	OS (60), ES (10) CH (1)	49, 46	1 (12.5 %)	IV
10. Li et al.[47]	2020	21	OS (13), ES (5), Other (3)	31, 30	1 (4.8 %)	IV
11. Paholpak et al.[48]	2015	12	OS (8), ES (2), Other (2)	40, 32	1 (8.3 %)	IV
12. Subhadrabandhu et al.[49]	2015	19	OS (16), CH (3)	67, 60	2 (10.5 %)	IV
13. Takeuchi et al.[50]	2018	12	OS (12)	63, 58	1 (8.3 %)	IV
14. Tsuchiya et al.[17]	2010	22	OS (18), ES (2), Other (2)	29, 24	3 (13.6 %)	IV
15. Yang et al.[12]	2015	25	OS (7), ES (4), CH (4), Other (10)	57, 50	3 (12 %)	IV
16. Zekry et al.[23]	2017	26	OS (21), Other (5)	59, 43	4 (15.4 %)	IV

* Median no provided; per the study all patients were followed 24–36 months.

The recycled autograft technique is associated with several advantages compared to other limb salvage reconstruction options, including relative cost, availability, preservation of osteoconduction and osteoinduction properties, optimal anatomic matching, soft tissue reattachment options, and lack of disease transmission and graft rejection possibilities [18,19]. However, concerns regarding the lack of histopathologic evaluation regarding completeness of resection and fear of reimplanting viable tumor cells increasing the risk for local recurrence have limited the use of this technique. Small cases series have reported recurrence rates ranging from 0 % to 15 % for the recycled autograft limb salvage reconstruction technique [20–23], which compare favorably to the 15 % to 30 % local recurrence rates reported for limb salvage techniques that do not utilize the resected bone segment for reconstruction [24–27]. However, a comprehensive review and compilation of available data have not been performed to the authors’ knowledge. Therefore, the goal of this study was to perform a systematic review of the peer-reviewed literature in order to provide a reliable local recurrence rate for treatment of primary bone sarcomas using a recycled autograft limb salvage reconstruction technique.

2. Methods

2.1. Search strategy

A systematic search of the literature through the search engines PubMed and Google Scholar was performed on 2 November 2023, following the Preferred Reporting Items for Systematic Reviews and Meta-Analyses guidelines. The search was conducted with the following Boolean terms: Bone Sarcoma AND (Liquid Nitrogen OR Recycled Autograft). Article and data deduplication was performed manually.

All titles and abstracts were screened, eliminating duplicates and articles irrelevant to this review. Following this, a full-text review of the remaining articles was performed based on inclusion and exclusion criteria.

2.2. Selection criteria

Full-text articles in English, French, Portuguese or Spanish published between 2008 and 2023 were included if the study presented sufficient information regarding patients with a diagnosis of a primary bone sarcoma of the limbs or pelvis who had undergone limb salvage reconstruction using liquid nitrogen recycled autografts (Fig. 1). Required information included:

- Patient age and gender

- Tumor location
- Tumor diagnosis
- Follow up time
- Recycle autograft technique
- Recurrence status

Exclusion criteria included studies with incomplete information, non-human or in vitro studies, abstract-only studies, and manuscripts without full text available.

2.3. Quality assessment

For included articles, risk of bias was assessed using the JBI critical appraisal checklist [28]. The articles included in the systematic review include case series of patients and were assessed regarding the possibility of bias, reporting of the cases and the statistical analysis presented. Using this tool, the examiner judged each domain according to specific criteria and then assigned an overall judgment for risk of bias for the study being analyzed. Additionally, the level of evidence was assessed and recorded in Table 1.

3. Results

Initial search identified 303 articles for assessment for eligibility. After duplicates were manually removed and exclusions were made, 40 articles remained for screening. Twenty-six articles had full pertinent text available, those were subjected to quality assessment. Finally, sixteen studies were included for synthesis and analysis (Table 1). Eleven articles were exclusively about patients with bone sarcoma, and the other 5 articles included patients with bone sarcomas as well as a small number of patients with metastatic disease from other primary sites (ex.: renal cell carcinoma), the latter patients were not considered for the analysis and only patients with primary bone sarcoma were included and evaluated. All articles included passed the JBI overall appraisal checklist. All the articles analyzed were Level IV of evidence (case series).

3.1. Population

From the 16 studies, a total of 286 patients with sarcoma treated with liquid nitrogen recycled autografts were included. The mean age of the patients was 23.1 years of age (range 2–74), with a median age of 16 years of age. In terms of gender there was a similar distribution, 133 (46.5 %) patients were female and 153 male (53.5 %). Most tumors were located in the femur ($n = 137$, 47.9 %), followed by the tibia ($n = 95$, 33.2 %) and the humerus ($n = 28$, 9.8 %). Eighteen patients had a pelvic tumor, and the remaining less frequent locations were the fibula ($n = 3$), radius ($n = 3$), ulna ($n = 1$) and calcaneus ($n = 1$). Osteosarcoma was the most frequent diagnosis ($n = 201$, 70.3 %), followed by Ewing sarcoma ($n = 37$, 12.9 %) and chondrosarcoma ($n = 21$, 7.3 %).

3.2. Interventions

Ten studies reported information regarding the freezing autograft technique used, this included information about 220 patients. Of those patients, 140 had a free intercalary autograft and 80 had a pedicled autograft. For limb salvage reconstruction, most patients had the autograft anatomically reimplanted and attached to the host bone using internal fixation ($n = 225$, 78.7 %), 47 (16.4 %) patients had a composite reconstruction with joint replacement, and 14 (4.9 %) patients had the construct reinforced with a vascularized fibula autograft.

3.3. Outcomes

When studies were synthesized, mean and median follow-up times were 47.8 months (range 5–164, SD 34.4) and 40 months, respectively

(Table 2). Local recurrences occurred in 25 patients (8.7 %). Local recurrences occurred in patients with mean and median ages of 22.5 years (range 7–60, SD 16.7) and 15 years, respectively. There was a higher proportion of males in the local recurrence subgroup (76.0 %) when compared to the total patient population (51.1 %) (Fisher's Exact, $p = 0.02$). The proportion of tumors in the femur was also higher in the local recurrence subgroup when compared to the total patient population (84.0 % vs. 44.4 %) (Fisher's Exact, $p < 0.001$). Osteosarcoma was the most common diagnosis among patients with local recurrences (68.0 %) and limb salvage reconstructions techniques were distributed among anatomic-internal fixation (76.0 %), composite with joint replacement (20.0 %) and vascularized fibula autograft reinforcement (4.0 %).

4. Discussion

The gold standard surgical treatment for primary bone sarcomas has advanced from amputation to limb salvage reconstruction. This advance in care has been possible through innovations in radiotherapy, chemotherapy, immunotherapy, implants, orthoses, and surgical techniques [29,30]. After bone tumor resection, various options for limb salvage reconstruction can be considered, including biologic and artificial alternatives. The non-biologic options are primarily focused on mega-prostheses, implants designed to replace larger segments of bone than typically required for standard joint replacement. Based on the vast experience with these implants reported in the peer-reviewed literature, their benefits include broad applicability across tumor types and locations, patients' immediate weight bearing status after limb salvage surgery, and good short- and medium-term implant survivorship [31–33]. Relative disadvantages include higher costs, limited availability, and suboptimal long-term outcomes, particularly in younger patients who may require repeated revisions throughout their lifetime [34]. Biologic options include allografts, distraction osteogenesis, vascularized fibula autografts, and recycled autografts. For the recycled autograft option, bone can be treated using pasteurization, irradiation, autoclave, or liquid nitrogen prior to reimplantation [35]. The liquid nitrogen technique [14] may be free or pedicled [15] and may be used alone or in combination with a vascularized fibula autograft [16] or artificial joint replacement [17]. Its relative advantages include lower costs, availability, preservation of osteoconduction and osteoinduction properties, optimal anatomic matching, soft tissue reattachment options, and lack of disease transmission and graft rejection possibilities [18,19,36]. However, concerns regarding potential lack of completeness of tumor resection and/or reimplantation of viable tumor cells resulting in high rates of local recurrence have limited the use of this technique. Additional concerns regarding this technique include risk of infection and nonunion at the osteotomy site, but again these complications are also attributed to allografts which have a more widespread use than autografts [11,37]. This reinforces the idea that concern for local recurrence when reimplanting the recycled bone segment could be the main limitation to a more prevalent application of recycled autografts.

Systematic review of the peer-reviewed literature providing data for 286 patients determined a local recurrence rate of 8.7 % during the first 4 years following limb salvage reconstruction using recycled autografts for treatment of primary bone sarcomas. This recurrence rate compares favorably to those reported for patients undergoing limb salvage reconstruction using artificial implants, which range from 15–30 % [24–27]. Importantly, previous studies have reported similar rates of non-oncologic complications and revisions as well as limb salvage construct survivorship when comparing reconstruction options [38–40]. For the recycled autograft reconstruction technique evaluated in this systematic review, relative risk factors for local recurrence may include younger patient age, male sex, and femoral tumor location such that these variables should be included when considering this treatment option. Our systematic review also found similar profile distribution of patients in terms of age (23 vs 26 vs 20–30), gender (male 54 % vs 55 % vs 49 %), diagnoses (osteosarcoma most frequent) and tumor location

Table 2
Total sample demographics (n = 286).

Variable	Value
Age in years	23.1 (2–74)
Men	153 (53.5 %)
Diagnosis	
Osteosarcoma	201 (70.3 %)
Ewing Sarcoma	37 (12.9 %)
Chondrosarcoma	21 (7.3 %)
Other	27 (9.4 %)
Tumor Location	
Femur	137 (47.9 %)
Tibia	95 (33.2 %)
Humerus	28 (9.8 %)
Pelvis	18 (6.3 %)
Other	8 (2.8 %)
Follow-up in months	47.8 (5–164)
Local Recurrences	25 (8.7 %)
Autograft Technique (n = 220)	
Pedicled	80
intercalary	140
Reconstruction	
Internal Fixation	225 (78.7 %)
Composite	47 (16.4 %)
Vascularized Fibula	14 (4.9 %)

(femur location most frequent) when comparing recycled autograft cohorts (Table 2) and the current literature for allograft and endoprosthesis reconstructions [11,39,40].

This study has the limitations of systematic reviews that restrict conclusions and generalizability. When studying and analyzing rare diseases such as bone sarcomas, sample size is inherently limited. Additionally, common findings in these studies include lack of long-term outcomes, insufficient numbers/data for valid multivariate analyses to include other key variable, heterogeneity of the samples, and lack of randomized or head-to-head cohort comparison studies. Systematic review and synthesis of the peer-reviewed literature mitigates these limitations to a degree, however, comprehensive registry-based studies reporting long-term outcomes are needed in order to establish valid clinical recommendations.

5. Conclusion

Systematic synthesis of the current evidence regarding local recurrence rates following use of the liquid nitrogen recycled autograft technique for limb salvage reconstruction after bone sarcoma resection suggests a favorable comparison to other limb salvage reconstruction options. As such, this technique warrants further consideration as a viable option for indicated patients based on relative advantages regarding costs, availability, and biologic and surgical reconstruction benefits.

CRediT authorship contribution statement

Ana Cecilia Belzarena: Writing – review & editing, Writing – original draft, Project administration, Methodology, Investigation, Formal analysis, Data curation, Conceptualization.

Declaration of competing interest

The authors declare that they have no known competing financial interests or personal relationships that could have appeared to influence the work reported in this paper.

This is to certify that all authors have seen and approved the final version of the manuscript being submitted.

The article is the authors’ original work, hasn’t received prior publication and isn’t under consideration for publication elsewhere.

References

[1] Yang J, Ren Z, Du X, Hao M, Zhou W. The role of mesenchymal stem/progenitor cells in sarcoma: update and dispute. *Stem Cell Investig.* 2014;1:18. Published 2014 Oct 27. doi:10.3978/j.issn.2306-9759.2014.10.01.

[2] M.J. Klein, G.P. Siegal, Osteosarcoma: anatomic and histologic variants, *Am J Clin Pathol.* 125 (4) (2006) 555–581, <https://doi.org/10.1309/UC6K-QHLD-9LV2-KENN>.

[3] Cancer of the bones and joints - Cancer Stat Facts. (n.d.). SEER. <https://seer.cancer.gov/statfacts/html/bones.html>.

[4] L. Mirabello, R.J. Troisi, S.A. Savage, International osteosarcoma incidence patterns in children and adolescents, middle ages and elderly persons, *Int J Cancer.* 125 (1) (2009) 229–234, <https://doi.org/10.1002/ijc.24320>.

[5] P.C. Valery, M. Laversanne, F. Bray, Bone cancer incidence by morphological subtype: a global assessment, *Cancer Causes Control.* 26 (8) (2015) 1127–1139, <https://doi.org/10.1007/s10552-015-0607-3>.

[6] J.Y. Blay, E. Palmerini, J. Bollard, et al., SELNET clinical practice guidelines for bone sarcoma, *Crit Rev Oncol Hematol.* 174 (2022) 103685, <https://doi.org/10.1016/j.critrevonc.2022.103685>.

[7] Smolle MA, Szkandera J, Andreou D, Palmerini E, Bergovec M, Leithner A. Treatment options in unresectable soft tissue and bone sarcoma of the extremities and pelvis - a systematic literature review. *EFORT Open Rev.* 2020;5(11):799-814. Published 2020 Nov 13. doi:10.1302/2058-5241.5.200069.

[8] A. Matsunobu, R. Imai, T. Kamada, et al., Impact of carbon ion radiotherapy for unresectable osteosarcoma of the trunk, *Cancer.* 118 (18) (2012) 4555–4563, <https://doi.org/10.1002/cncr.27451>.

[9] Smolle MA, Andreou D, Tunn PU, Leithner A. Advances in tumour endoprostheses: a systematic review. *EFORT Open Rev.* 2019;4(7):445-459. Published 2019 Jul 2. doi:10.1302/2058-5241.4.180081.

[10] Goulding KA, Schwartz A, Hattrup SJ, et al. Use of Compressive Osseointegration Endoprostheses for Massive Bone Loss From Tumor and Failed Arthroplasty: A Viable Option in the Upper Extremity [Published correction appears in Clin Orthop Relat Res. 2017 Jun;475(6):1752]. *Clin Orthop Relat Res.* 2017;475(6):1702-1711. doi:10.1007/s11999-017-5258-0.

[11] L. Aponte-Tinao, G.L. Farfalli, L.E. Ritacco, M.A. Ayerza, D.L. Muscolo, Intercalary femur allografts are an acceptable alternative after tumor resection, *Clin Orthop Relat Res.* 470 (3) (2012) 728–734, <https://doi.org/10.1007/s11999-011-1952-5>.

[12] Yang J, Li W, Feng R, Li D. Intercalary frozen autografts for reconstruction of bone defects following meta-/diaphyseal tumor resection at the extremities. *BMC Musculoskelet Disord.* 2022;23(1):890. Published 2022 Sep 30. doi:10.1186/s12891-022-05840-6.

[13] G. Bianchi, L. Gaiero, N. Casales, C. Silveri, A.C. Belzarena, Recent Advances in Bone Tumours and Osteoarthritis, *IntechOpen.* (2021), <https://doi.org/10.5772/intechopen.96765>.

[14] H. Tsuchiya, S.L. Wan, K. Sakayama, N. Yamamoto, H. Nishida, K. Tomita, Reconstruction using an autograft containing tumour treated by liquid nitrogen, *J Bone Joint Surg Br.* 87 (2) (2005) 218–225, <https://doi.org/10.1302/0301-620x.87b2.15325>.

[15] El Masry, Ayman Mohammad et al. “Does A Single Osteotomy Technique for Frozen Autograft (Pedicled Freezing) in Patients With Malignant Bone Tumors of the Long Bones Achieve Union and Local Tumor Control?.” *Clinical orthopaedics and related research*, 10.1097/CORR.0000000000002788. 17 Aug. 2023, doi:10.1097/CORR.0000000000002788.

[16] M.K. Gundavda, et al., Reconstructive Challenges of Distal Tibia Bone Tumors: Extracorporeally Irradiated Autograft Combined with a Nonvascularized Autograft Fibula for Superior Reconstruction and Functional Outcomes When Compared to Ipsilateral Pedicled Fibula Transfer Alone, *Sarcoma* 2021(6624550), 23 (2021) Mar, <https://doi.org/10.1155/2021/6624550>.

[17] H. Tsuchiya, H. Nishida, P. Srisawat, et al., Pedicle frozen autograft reconstruction in malignant bone tumors, *J Orthop Sci.* 15 (3) (2010) 340–349, <https://doi.org/10.1007/s00776-010-1458-0>.

[18] K. Igarashi, N. Yamamoto, T. Shirai, et al., The long-term outcome following the use of frozen autograft treated with liquid nitrogen in the management of bone and soft-tissue sarcomas, *Bone Joint J.* (2014;96-B(4):555–561.), <https://doi.org/10.1302/0301-620X.96B4.32629>.

[19] M. Abdel Rahman, A. Bassiony, H. Shalaby, Reimplantation of the resected tumour-bearing segment after recycling using liquid nitrogen for osteosarcoma, *Int Orthop.* 33 (5) (2009) 1365–1370, <https://doi.org/10.1007/s00264-009-0773-6>.

[20] Hayashi K, Yamamoto N, Takeuchi A, et al. Clinical course of grafted cartilage in osteoarticular frozen autografts for reconstruction after resection of malignant bone and soft-tissue tumor involving an epiphysis. *J Bone Oncol.* 2020;24:100310. Published 2020 Aug 2. doi:10.1016/j.jbo.2020.100310.

[21] A.M. El Masry, S.I. Azmy, M.A. Rahman Mustafa, M.A. Abuelhadid, Does A Single Osteotomy Technique for Frozen Autograft (Pedicled Freezing) in Patients With Malignant Bone Tumors of the Long Bones Achieve Union and Local Tumor Control? *Clin Orthop Relat Res.* 482 (2) (2024) 340–349, <https://doi.org/10.1097/CORR.0000000000002788>.

[22] H. Özger, B. Alpan, L. Eralp, et al., Is liquid nitrogen recycled bone and vascular fibula combination the biological reconstruction of choice in lower extremity long bone tumor-related defects? *J Surg Oncol.* 128 (5) (2023) 902–915, <https://doi.org/10.1002/jso.27385>.

[23] K.M. Zekry, N. Yamamoto, K. Hayashi, et al., Intercalary frozen autograft for reconstruction of malignant bone and soft tissue tumours, *Int Orthop.* 41 (7) (2017) 1481–1487, <https://doi.org/10.1007/s00264-017-3446-x>.

[24] A. Gomez-Brouchet, E. Mascard, A. Siegfried, et al., Assessment of resection margins in bone sarcoma treated by neoadjuvant chemotherapy: Literature review

- and guidelines of the bone group (GROUPOS) of the French sarcoma group and bone tumor study group (GSF-GETO/RESOS), *Orthop Traumatol Surg Res.* 105 (4) (2019) 773–780, <https://doi.org/10.1016/j.otsr.2018.12.015>.
- [25] B.D. Crompton, R.E. Goldsby, V.K. Weinberg, R. Feren, R.J. O'Donnell, A.R. Ablin, Survival after recurrence of osteosarcoma: a 20-year experience at a single institution, *Pediatr Blood Cancer.* 47 (3) (2006) 255–259, <https://doi.org/10.1002/pbc.20580>.
- [26] R. Evans, et al., Local recurrence, rate and sites of metastases, and time to relapse as a function of treatment regimen, size of primary and surgical history in 62 patients presenting with non-metastatic Ewing's sarcoma of the pelvic bones, *International Journal of Radiation Oncology, Biology, Physics* 11 (1) (1985) 129–136, [https://doi.org/10.1016/0360-3016\(85\)90371-2](https://doi.org/10.1016/0360-3016(85)90371-2).
- [27] J.D. Stevenson, M.K. Laitinen, M.C. Parry, V. Sumathi, R.J. Grimer, L.M. Jeys, The role of surgical margins in chondrosarcoma, *Eur J Surg Oncol.* 44 (9) (2018) 1412–1418, <https://doi.org/10.1016/j.ejso.2018.05.033>.
- [28] Z. Munn, T.H. Barker, S. Moola, C. Tufanaru, C. Stern, A. McArthur, M. Stephenson, E. Aromataris, Methodological quality of case series studies: an introduction to the JBI critical appraisal tool, *JBI Evidence Synthesis.* 18 (10) (2020) 2127–2133.
- [29] Kotz, Rainer et al. "Advances in bone tumour treatment in 30 years with respect to survival and limb salvage. A single institution experience." *International orthopaedics* vol. 26,4 (2002): 197–202. doi:10.1007/s00264-002-0365-1.
- [30] Ayerza, Miguel A et al. "Does increased rate of limb-sparing surgery affect survival in osteosarcoma?." *Clinical orthopaedics and related research* vol. 468,11 (2010): 2854–9. doi:10.1007/s11999-010-1423-4.
- [31] B.o. Li, et al., Proximal femoral tumor resection followed by joint prosthesis replacement: a systematic review and meta-analysis, *BMC Musculoskeletal Disorders* vol. 24,1 (2 Oct. 2023,) 779, <https://doi.org/10.1186/s12891-023-06913-w>.
- [32] B. Boukebous, et al., What to improve: Results of fixed-hinge knee endoprosthesis reconstructions over 40 years in a single tumor center, *Orthopaedics & Traumatology, Surgery & Research : OTSR* 109 (7) (2023) 103682, <https://doi.org/10.1016/j.otsr.2023.103682>.
- [33] P.D. Rowell, et al., Endoprosthetic reconstruction for lower extremity soft tissue sarcomas with bone involvement, *Journal of Surgical Oncology* 128 (4) (2023) 660–666, <https://doi.org/10.1002/jso.27300>.
- [34] A. Dotan, S. Dadia, J. Bickels, et al., Expandable endoprosthesis for limb-sparing surgery in children: long-term results, *J Child Orthop.* 4 (5) (2010) 391–400, <https://doi.org/10.1007/s11832-010-0270-x>.
- [35] N.F. Yasin, et al., Which is the best method of sterilization for recycled bone autograft in limb salvage surgery: a radiological, biomechanical and histopathological study in rabbit, *BMC Cancer* 15 (289) (Apr. 2015) 15, <https://doi.org/10.1186/s12885-015-1234-9>.
- [36] Y. Tanzawa, et al., Histological examination of frozen autograft treated by liquid nitrogen removed 6 years after implantation, *Journal of Orthopaedic Science : Official Journal of the Japanese Orthopaedic Association* 13 (3) (2008) 259–264, <https://doi.org/10.1007/s00776-007-1222-2>.
- [37] L.A. Aponte-Tinao, M.A. Ayerza, J.I. Albergo, G.L. Farfalli, Do Massive Allograft Reconstructions for Tumors of the Femur and Tibia Survive 10 or More Years after Implantation? *Clin Orthop Relat Res.* 478 (3) (2020) 517–524, <https://doi.org/10.1097/CORR.0000000000000806>.
- [38] Y. Li, H. Xu, H. Shan, K. Ma, W. Liu, X. Niu, A comparative study of reconstruction modalities after knee joint-preserving tumor resection: reconstruction with a custom-made endoprosthesis versus reconstruction with a liquid nitrogen-inactivated autologous bone graft, *J Orthop Surg Res.* 18(1):908 (2023), <https://doi.org/10.1186/s13018-023-04402-3>. Published 2023 Nov 29.
- [39] P. Thornley, M. Vicente, A. MacDonald, N. Evaniew, M. Ghert, R. Velez, Causes and Frequencies of Reoperations After Endoprosthetic Reconstructions for Extremity Tumor Surgery: A Systematic Review, *Clin Orthop Relat Res.* 477 (4) (2019) 894–902, <https://doi.org/10.1097/CORR.0000000000000630>.
- [40] E.J. Geiger, et al., What Is the Long-term Survivorship of Primary and Revision Cemented Distal Femoral Replacements for Limb Salvage of Patients With Sarcoma? *Clinical Orthopaedics and Related Research* 481 (3) (2023) 460–471, <https://doi.org/10.1097/CORR.0000000000002333>.
- [41] Z. Dai, Y. Sun, M. Maihemuti, R. Jiang, Follow-up of biological reconstruction of epiphysis preserving osteosarcoma around the knee in children: A retrospective cohort study, *Medicine (baltimore).* 102 (10) (2023) e33237.
- [42] Emet A, Demirtas Y, Beydemir A, Ayvaz M. Comparison of the Results of Patients Treated With Limb-Sparing Treatment Options in Malignant Bone Tumors: Sharing the Experience of Twelve Bicentric Patients. *Cureus.* 2023;15(9):e46270. Published 2023 Sep 30. doi:10.7759/cureus.46270.
- [43] S.K. Garg, P. Aggarwal, J. Virk, R.P.S. Punia, K. Dimri, R. Jindal, Limb Salvage Using Liquid Nitrogen-Treated Tumour-Bearing Autograft: A Single Institutional Experience of 10 Patients, *Indian J Orthop.* 54 (2) (2020) 200–207, <https://doi.org/10.1007/s43465-019-00001-9>. Published 2020 Jan 13.
- [44] T. Higuchi, N. Yamamoto, H. Nishida, et al., Knee joint preservation surgery in osteosarcoma using tumour-bearing bone treated with liquid nitrogen, *Int Orthop.* 41 (10) (2017) 2189–2197, <https://doi.org/10.1007/s00264-017-3499-x>.
- [45] S. Hindiskere, S. Doddarangappa, P.S. Chinder, What Are the Challenges and Complications of Sterilizing Autografts with Liquid Nitrogen for Malignant Bone Tumors? A Preliminary Report, *Clin Orthop Relat Res.* 478 (11) (2020) 2505–2519, <https://doi.org/10.1097/CORR.0000000000001347>.
- [46] J. Li, F. Zhang, M. Yang, et al., Extracorporeally frozen tumour-bearing bone combined with free vascularised fibula for the intercalary reconstruction of femoral defect after resection of bony sarcoma, *J Plast Reconstr Aesthet Surg.* 69 (6) (2016) 856–863, <https://doi.org/10.1016/j.bjps.2016.02.018>.
- [47] Y. Li, Y. Yang, Z. Huang, H. Shan, H. Xu, X. Niu, Bone defect reconstruction with autologous bone inactivated with liquid nitrogen after resection of primary limb malignant tumors: An observational study, *Medicine (baltimore).* 99 (24) (2020) e20442.
- [48] P. Paholpak, W. Sirichativapee, T. Wisanuyotin, W. Kosuwon, P. Jeeravipoolvarn, Clinical results of primary malignant musculoskeletal tumor treated by wide resection and recycling autograft reconstruction using liquid nitrogen, *Asia Pac J Clin Oncol.* 11 (2) (2015) 114–120, <https://doi.org/10.1111/ajco.12197>.
- [49] S. Subhadrabandhu, A. Takeuchi, N. Yamamoto, et al., Frozen Autograft-Prosthesis Composite Reconstruction in Malignant Bone Tumors, *Orthopedics.* 38 (10) (2015) e911–e918, <https://doi.org/10.3928/01477447-20151002-59>.
- [50] A. Takeuchi, N. Yamamoto, K. Hayashi, et al., Growth of epiphysis after epiphyseal-preservation surgery for childhood osteosarcoma around the knee joint, *BMC Musculoskelet Disord.* 19(1):185 (2018), <https://doi.org/10.1186/s12891-018-2109-4>. Published 2018 Jun 6.